



Rare Case of Complete Fatty Degeneration of the Paraspinal Muscle in a Patient with Low Back Pain

Bel Ağrılı Bir Olguda Nadir Gözlenen Paraspinal Adale Komplet Yağlı Dejenerasyonu

Paraspinal Fatty Degeneration

İbrahim Burak Atcı¹, Hakan Yılmaz², Mustafa Yavuz Samancı¹, Oğuz Baran¹, Mehmet Yaman¹
¹Beyin ve Sinir Cerrahisi Kliniği, İstanbul Eğitim ve Araştırma Hastanesi,
²Beyin ve Sinir Cerrahisi Kliniği, Düzce Atatürk Devlet Hastanesi, Düzce, Türkiye

Özet

Bel ve sırt ağrılarının etyopatogenezi her zaman ortaya konulamamakta, bazen klinisyenler klinik bulgularla radyolojik tetkikler arasında ilişki kuramamaktadırlar. Klinisyenler bel ve sırt ağrılarında görüntüleme çoğunlukla vertebra cismi, intervertebral disk ve faset eklemlere odaklanma eğilimindedir. Ancak görüntülemelerde lomber omurga stabilizasyonunda önemli rol oynayan paravertebral kaslar göz ardı edilmemelidir. Lomber bölgede yağ depoziti miktarındaki artış ve kas kitlesinin azalması makroskopik olarak kas dejenerasyonu bulgusudur. Bu olgu sunumu kronik bel ağrısı nedeni tarafımıza başvuran ve görüntüleme raporunda 2 seviye bulging dışında patolojik bulgu olmayan bir hastanın tarafımızca incelenen görüntülemesinde paravertebral adalelerde kas dokusunun tamamen yağlı dejenerasyona uğradığı ve lomber omurga stabilitesinde önemli rol oynayan kasların volümlerini kaybederek atrofi olduğu görüldüğü nedeniyle yapılmıştır.

Anahtar Kelimeler

Kronik Bel Ağrısı; Paraspinal Adale; Yağlı Dejenerasyon

Abstract

The etiopathogenesis of low back pain cannot always be demonstrated and sometimes clinicians cannot establish a relationship between clinical symptoms and radiological examinations. Clinicians tend to focus on vertebral body, intervertebral discs, and facet joints on imaging in low back pain. However, the paravertebral muscles that play an important role in lumbar spine stabilization should not be underestimated on imaging. The increase in the amount of fat deposited in the lumbar region and the reduction of muscle mass are macroscopic findings of muscle degeneration. In this case report, we present a patient with chronic low back pain who had been reported to have no pathological findings except 2 levels of bulging on previous imaging and who was then diagnosed as having complete fatty degeneration and atrophy of the paravertebral muscles after reevaluation of her imaging results.

Keywords

Chronic Low Back Pain; Paraspinal Muscle; Fatty Degeneration

DOI: 10.4328/JCAM.4137

Received: 23.11.2015 Accepted: 15.12.2015 Printed: 01.03.2016

J Clin Anal Med 2016;7(2): 276-8

Corresponding Author: Hakan Yılmaz, Beyin ve Sinir Cerrahisi Kliniği, Düzce Atatürk Devlet Hastanesi, Düzce, Türkiye.

GSM: +905066211829 E-Mail: dr_hakanyilmaz@hotmail.com

Introduction

Low back pain is a very common health problem worldwide and at least 80% of the population complains of low back pain once during their lives [1]. Although pain is often due to a single cause, there is more than one source of pain in some cases. Low back pain is considered to be chronic if it has been present for longer than 3-6 months despite medical treatment [2]. Pathology of vertebral body, intervertebral disc and facet joint, social-psychological factors, and muscle spasms are effective in the formation of acute and chronic pain. Neuroimaging is utilized during the diagnosis of patients with chronic pain. In most cases, mismatches emerge between radiology and clinical symptoms and lumbar magnetic resonance imaging (MRI) is interpreted as normal after evaluating mostly vertebral body, intervertebral discs, and facet joints. The paravertebral muscles, which play a key role in the biomechanics and stability of the lumbar region, are also not fully evaluated and ignored by radiology physicians [1,3].

In this case report, a 28-year-old female patient was admitted to our outpatient clinic with complaints of persistent back pain lasting for 1 year and she was diagnosed as having severe paraspinal fatty degeneration with radiological examination. This rare massive paravertebral fatty degeneration is presented in order to emphasize the necessity of evaluating the paraspinal muscles that play an important role in motion and posture and the importance of this evaluation in terms of guiding the clinician to correct treatments in patients with chronic low back pain.

Case Report

A 28-year-old female patient was admitted to the neurosurgery outpatient clinic with a complaint of back pain lasting for 1 year, increasing during the day with prolonged movement and standing, while decreasing with medical treatment and at night. The patient did not have any leg pain. The patient's body mass index was 25.1. Neurological examination revealed no neurological deficits, nerve tension tests were negative, and there were trigger point tenderness and paravertebral muscle spasm, but the waist movements were painful. Laboratory tests required to rule out inflammatory and infectious pathology were negative. The pain was thought to result from instability, so lumbosacral spine radiographs were ordered. X-ray of the lumbar vertebrae revealed no pathologic findings and L4-5 and L5-S1 minimal bulging were reported in lumbar magnetic resonance imaging (MRI). Examination of T2-weighted axial Lumbar MRI sections revealed severe fatty degeneration of multifidus, longissimus and erector spinae muscles, and volume loss in psoas muscle (Grade 4 – there is more fat than muscle tissue) (Figure 1). In order to improve decreased force and endurance in muscles that support the movement of the spine, the patient was enrolled in a rehabilitation program in consultation with physical medicine and a rehabilitation clinic.

Discussion

There is a tendency by clinicians and radiology experts to focus on lumbar intervertebral discs, vertebral bodies, and facet joints during evaluation of radiological imaging of patients with lower back pain. This leads to the overlooking of the pathol-

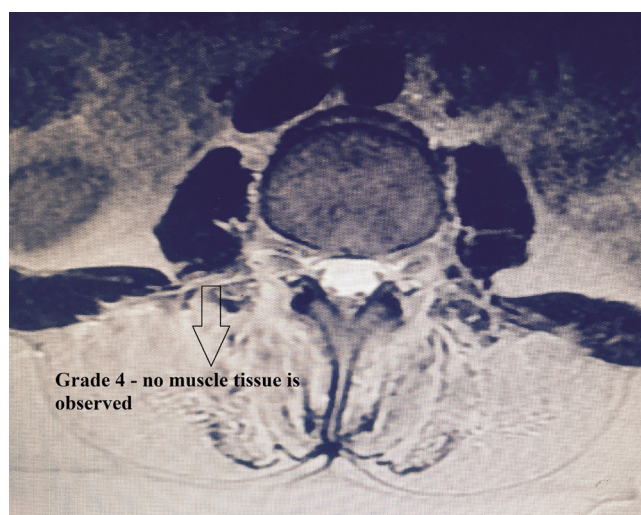


Figure 1. Axial section of current patient. Posterior muscle groups are observed to undergo fatty degeneration completely and no muscle tissue is observed.

ogy of paravertebral muscle, one the most important elements of spine biomechanics and stability. Weakening of the spinal muscle strength, paravertebral muscle volume reduction, and the resulting fatty degeneration lead to postural dysfunction and chronic back pain in the future [4].

Muscles groups supporting the stability of the spine are erector spinae muscles posteriorly and psoas and rectus abdominis muscles anteriorly. Erector spinae muscles are composed of three layers: iliocostalis, longissimus ve spinalis. This muscle group is located between the transverse processes of the vertebrae. The most medially located spinal muscle group is multifidus muscle, which fill up the groove on either side of the spinous processes of the vertebrae. These three muscles allow the extension and bending of the vertebral column to one side. In biomechanical studies, multifidus muscle was found to be the most effective muscle in lumbar stability. This muscle is the largest of the muscles surrounding the lumbar spine and it has a limiting effect on flexion and lateral bending, in addition to the function of maintaining lumbar lordosis. In many studies on patients with chronic low back pain, muscle changes have been found to occur mostly in multifidus muscles [5].

Macroscopic evaluation of muscle degeneration and volume loss can be done with MRI. Increase in fat deposits in the connective tissue can be demonstrated with muscle volume measurement by MRI [6]. In the literature, rotator cuff muscles fatty degeneration measuring scale (Goutallier classification) is being used for measuring the amount of fatty degeneration. In this scale, axial cross-section of lumbar 4 – 5 intervertebral area on T2-weighted MRI sequences is evaluated and the degree of atrophy and fatty degeneration of multifidus, longissimus, and psoas muscle is determined (Figure 2). Accordingly: Grade 0: normal muscle, grade 1: some fatty streaks, grade 2: less than 50% fatty muscle atrophy, grade 3: 50% fatty muscle atrophy, and grade 4: greater than 50% fatty muscle atrophy [7]. In our case, fatty degeneration was dominant in nearly all of the lumbar paraspinal muscles and there was also volume loss and fatty degeneration in psoas muscle (Grade 4).

There are biomechanical and clinical studies on the fatty degeneration of paravertebral muscles in the literature. Increase in the amount of fat deposits and reduction in muscle mass

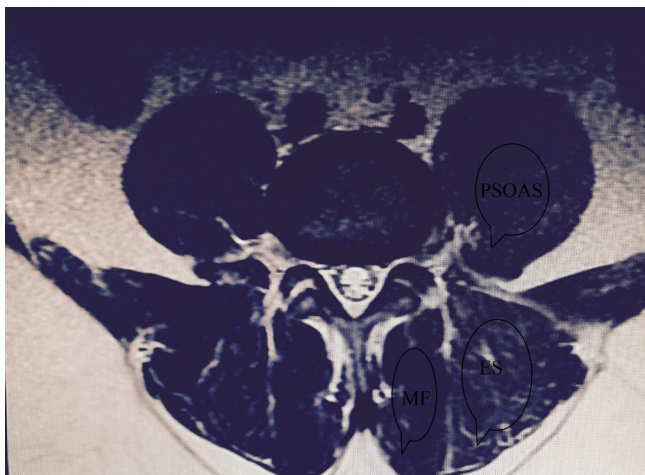


Figure 2. Normal lumbar MRI. Posterior muscle group, iliocostalis muscle - longissimus muscles (erector spinae), multifidus muscle and anterior psoas muscle are seen with regular volume and muscle mass at L4-L5 level on axial section.

are among the macroscopic findings of muscle degeneration. Muscle atrophy is thought to occur due to disuse or denervation of the muscle [8]. In these studies, the question of whether the muscle degeneration initiates the pain or the pain leads to degeneration has not received a clear answer and remains a contentious issue. In some studies, degenerative changes in muscles were reported to occur depending on self-protection and immobilization of the patient due to back pain. Volume changes in the cervical region of the paraspinal muscles are not considered as significantly important as changes as in the lumbar region because of the different impact of the limitations of head movements or waist movements on everyday life [8]. A literature review of this subject revealed that fatty degeneration of paravertebral muscles occurs particularly in the multifidus muscle, that two posterior muscle groups accompany degeneration in a limited number of cases, and that most of the cases have grade 3 and 4 degeneration (Figure 3). In grade

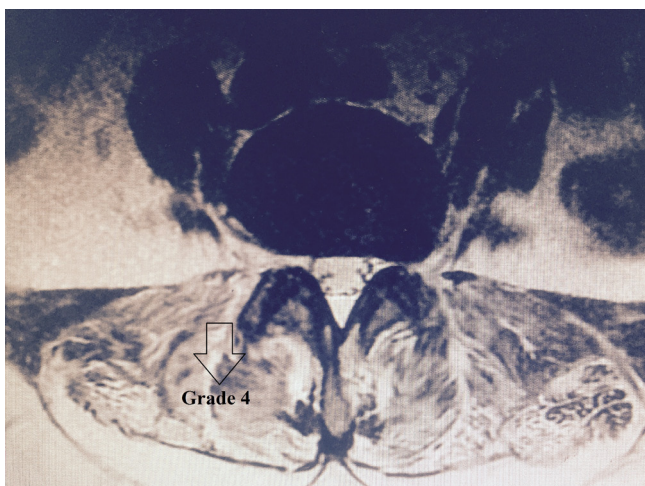


Figure 3. L4-L5 axial sections of another patient with Grade 4 fatty degeneration. Fat tissue is observed to be more than muscle tissue.

4 patients, fatty degeneration is present, particularly in interstitial connective tissue elements, and fat mass is more than muscle mass [7]. In our case, the muscles in the posterior paravertebral region were observed to have atrophied completely, and there was almost no muscle tissue. To our knowledge, in the literature, there is not such a reported case for a patient under the age of 50.

Conclusion

It should be known that chronic back pain is due to multifactorial etiology and it should be particularly kept in mind that paravertebral muscles and psoas muscle, one of the three main elements of stability, should be considered carefully in every imaging study. Clear distinction of fatty degeneration will be easier after a certain familiarity regarding clinicians, when careful consideration of the paravertebral muscles is done. As a result, it will be possible to bring chronic low back pain patients back to everyday life following appropriate treatment and exercises.

Acknowledgements

We would like to thank all the members of staff at our department for their valuable efforts during the study period.

Competing interests

The authors declare that they have no competing interests.

References

1. Rubin DI. Epidemiology and risk factors for spine pain. *Neurol Clin* 2007;25:353-71.
2. Facco E, Ceccherelli F. Myofascial pain mimicking radicular syndromes. *Acta Neurochir* 2005;92(Suppl):147-50.
3. Kader DF, Wardlaw D, Smith FW. Correlation between the MRI changes in the lumbar multifidus muscles and leg pain. *Clin Radiol* 2000;55:145-9.
4. Danneels LA, Vanderstraeten GG, Cambier DC, Witvrouw EE, De Cuyper HJ. CT imaging of trunk muscles in chronic low back pain patients and healthy control subjects. *Eur Spine J* 2000;9:266-72.
5. Cyron BM, Hutton WC. Articular tropism and stability of lumbar spine. *Spine* 1980;24:168-172.
6. Yoshihara K, Shirai Y, Nakayama Y, Uesaka S. Histochemical changes in the multifidus muscle in patients with lumbar intervertebral disc herniation. *Spine* 2001;15:622-6.
7. Mengiardi B, Schmid MR, Boos N, Pfirrmann CW, Brunner F, Elfering A, et al. Fat content of lumbar paraspinal muscles in patients with chronic low back pain and in asymptomatic volunteers: Quantification with MR Spectroscopy. *Radiology* 2006;240:786-92.
8. Alaranta H, Luoto S, Heliovaara M, Hurri H. Static back endurance and the risk of low back pain. *Clin Biomech* 1995;10:323-4.

Informed Consent

Written informed consent was obtained from patients who participated in this study.

How to cite this article:

Atcı İB, Yılmaz H, Samancı MY, Baran O, Yaman M. Rare Case of Complete Fatty Degeneration of the Paraspinal Muscle in a Patient With Low Back Pain. *J Clin Anal Med* 2016;7(2): 276-8.